

# Restorative Challenge in the

– Interdisciplinary implant management for a maxillary alveolar traumatic defect



**Ronald Cody,  
DMD**

General Practice,  
Portland, Maine



**Robert  
Schaedel,  
MD, DMD**

Oral Surgeon,  
Portland, Maine

A multidisciplinary team approach in implant dentistry is imperative to providing the best possible result. A combination of diagnostic evaluation, restorative technique, oral surgery, dento-alveolar implant selection, periodontics, and material science, come together to support the high demands of anterior implant dentistry. The planning and sequencing of a team of lab technicians and surgeons guided by a restorative dentist can achieve predictability in correct surgical site development, implant placement and perio-restorative treatment success. The selection of a proper dento-alveolar implant system is critical to periodontal site development and stability in these cases.

A 29-year-old fire fighter presented 5 years after traumatic loss of the maxillary right central and lateral incisor with fracture of the maxillary left central incisor. Past prosthetic management included only a removable temporary partial denture.

Over the past few years his wife had addressed concerns about the esthetic appearance and finally she convinced him to consider an implant-supported restoration.

## Examination and Treatment Planning

Upon examination of the edentulous area, a significant alveolar defect was noted with loss of inter-dental structure (Fig. 1a and b). The alveolar area and dental structures were diagnostically waxed to illustrate the dimension and position of the defect. A matrix of this area was made, and cross-referenced to the original cast (Fig. 2). According to this matrix dimension, a significant portion of cortical bone was harvested in the ramus grafted to the site (Fig. 3) utilizing closure materials and technique. The patients existing

partial denture was relined and repositioned for a healing period of four months.<sup>1</sup> Subsequent to this four month period, a surgical positioning template was made from a light cured acrylic material (Triad, Dentsply Int., PA) for the positioning of 2 implants, one 4.5 ST and one 3.5 fixture.

## Surgical Protocol

This template contained the exact diagnostic position of the cervical 1/3 of the teeth, so that the vertical positioning of the implant relative to the CEJ could be ascertained at 3 mm apical (Fig. 4). Also, careful attention

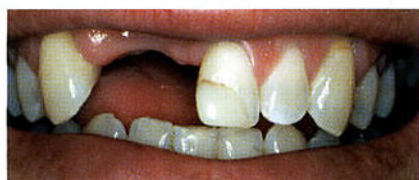

Fig. 1a

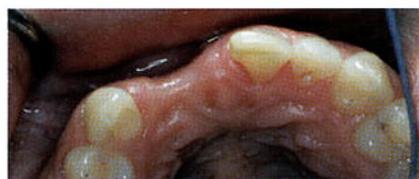

Fig. 1b

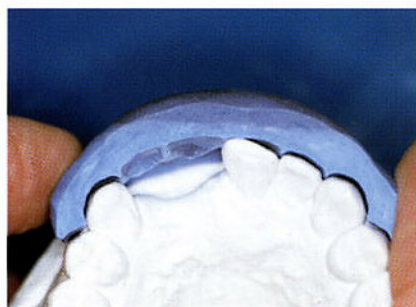

Fig. 2

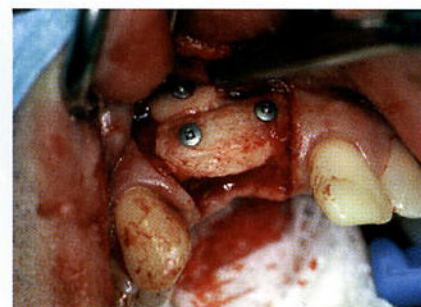


Fig. 3



# Esthetic Zone



was given to emergence of the implant axis from the cingulum position of the diagnostic cast. A separate acrylic transfer template from the master cast was utilized with fixture impression copings immediately following surgical placement of the fixtures (Fig. 4) and registration of the implant position was achieved (Triad liquid, Dentsply

Int., PA), and the surgical site was closed. The patient then had his removable partial denture relined over a six month healing period utilizing a soft reline material (Generic Pentron, Jeneric/Pentron Inc., CT).

## Temporization

Fixture analogs were attached to the

impression copings and the template was connected to the sectioned master cast, and an altered cast registration was made. Temporary abutment cylinders were attached to the altered cast, and cut to a correct vertical position (Fig. 5). Pink composite opaquer was applied to the cylinder, and the temporaries were built from composite utilizing a clear direct template matrix of teeth on the diagnostic cast. At surgical uncover, this fixture level provisional (Fig. 6) was delivered and utilized to aid the surgeon in soft tissue positioning, and closure was achieved around this diagnostically determined emergence profile. Abutment screw access channels were closed with light cured temporary material (Fermit, Ivoclar Vivadent Inc., NY). These temporaries were lightly refined during initial healing. Preparation and temporization of tooth #9 was performed. These temporaries were verified as comfortable both phonetically and functionally, and were esthetically pleasing to the patient (Fig. 7).

## Laboratory Procedure

Subsequent to periodontal healing, (Fig. 8) final impressions, facebow

*Continued on next page*

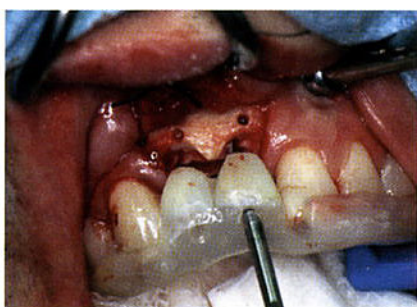

Fig. 4

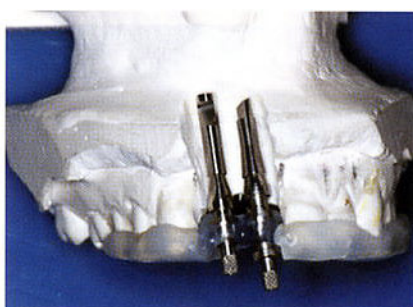


Fig. 5

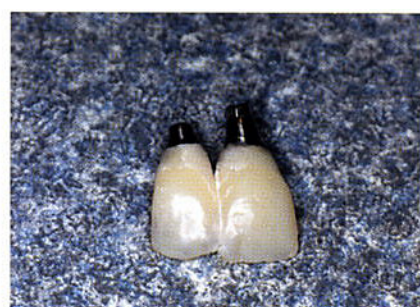

Fig. 6



transfer, bite registration, and 35 mm color slide series were taken and delivered to the dental laboratory. Verification of restorative position was transferred to the laboratory with a facebow mounted cast of the provisionals. The Cast-to Astra Tech abutment was utilized and the ceramo-metal frameworks were waxed directly to the abutment. This provided for an abutment cast restoration, allowing predictability in delivery and management of the restorations at the fixture level without a dual abutment/crown cementation.

The slides provided were analyzed to establish shade selection and overall tooth characterization.

Utilizing an incisal matrix, the crowns were built to the position of the provisional crowns. A1 and A2 shade tabs were used in the slides and provided as a basic shade for the crowns per the prescription. A modified 3MI shade was used for the

final restorations. Vita Interno stains (Vivadent Inc., CA) were used for internal character. Internos used in thin amounts allowed color application that was subtle and did not shadow or block light. The most challenging part of the final tooth contour was the lack of tissue present. To fill in the papilla void, long contacts were necessary as well as subtle facial embrasure variants.

### Final Restorative Result

The restorations (Fig. 9) were delivered to the patient and seated with 25 Ncm.

The survival of bone levels being imperative to the maintenance and establishment of papillae in implant periodontal tissues has been documented in numerous publication.<sup>2-7</sup>

This clinical case shows excellent stability and appearance of the peri-implant tissues and that it can be achieved in areas where ridge trauma and bone loss have occurred

Finally – the clinical restorative team along with the proper implant system, can achieve dramatic results in restorative compromised situation in the esthetic zone (Fig. 10-12). ■

### References

1. R G TriPlett, S R Schow Autologous Bone Grafts and Endosseous Implants: Complementary Techniques.
2. Enquist, B et al. Marginal Bone Reaction to Oral Implants: A Prospective Comparative Study of Astra Tech and Branemark System Implants.
3. Palmer, R et al. A 5 Year Prospective Study of Astra Single Tooth Implants.
4. Puchades-Roman, L et al. A Clinical, Radiographic, and Microbiologic Comparison of Astra Tech and Branemark Single Tooth Implants.
5. Astrand, P et al. Astra Tech and Branemark System Implants: A Prospective 5-Year Comparative Study After One Year.
6. Norton, M. Marginal Bone Levels at Single Tooth Implants with a Conical Fixture Design. The Influence of Surface Macro- and Microstructure.
7. Rasmusson, L et al. Effects of Implant Design and Surface on Bone Regeneration and Implant Stability: An Experimental Study in the Dog Mandible.

The authors like to thank our two other members of the restorative team:  
Kyle Swan, Ceramist, CDT Functional Esthetics and  
Jill Gaziano, Periodontist, DMD, MS

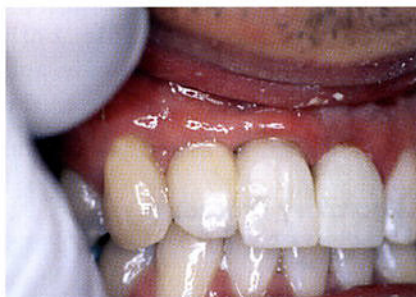

Fig. 7

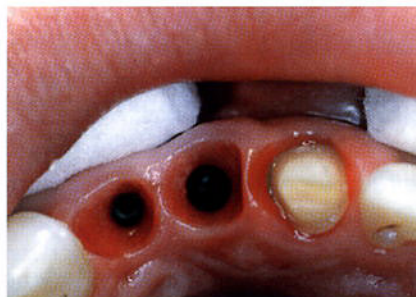

Fig. 8

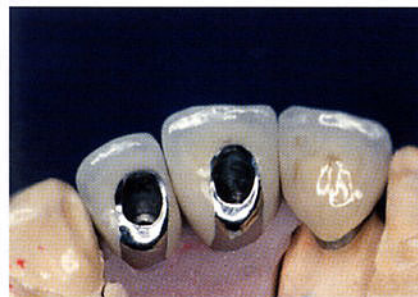

Fig. 9

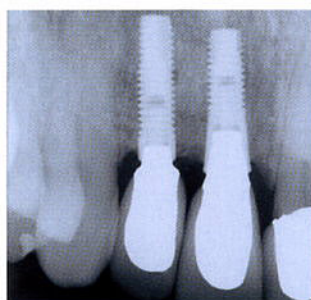

Fig. 10

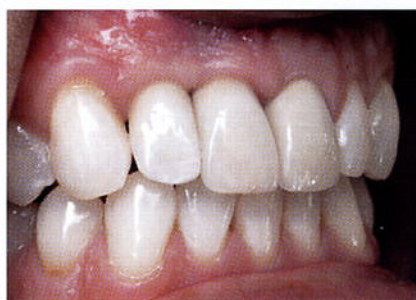

Fig. 11

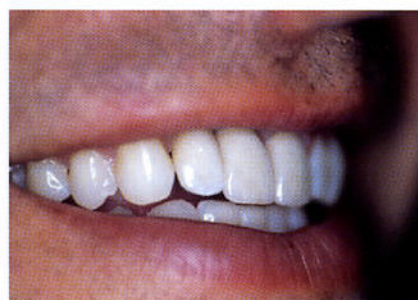

Fig. 12