

Ronald Cody, DMD

Private Practice, Portland, Maine, USA

Jim Lawlor, CDT

Functional Esthetics Dental Laboratory,
Lewisville, Texas, USA



Ronald Cody



Jim Lawlor

Abutment selection for individual esthetic results

—A two case comparative presentation.

The Astra Tech dental implant system offers a variety of abutment options for each individual restoration. A clinician may choose from a range of abutment types to include pre-designed ceramic abutments, pre-designed titanium abutments, prefabricated abutments, Direct Abutments, or Cast-to abutments for their dental implant restorations.

The factors that influence abutment selection include the location and esthetic demand (anterior or posterior; maxilla or mandible), force load, implant position, angulation and depth, and material selection for the suprastructure in the definitive restoration.

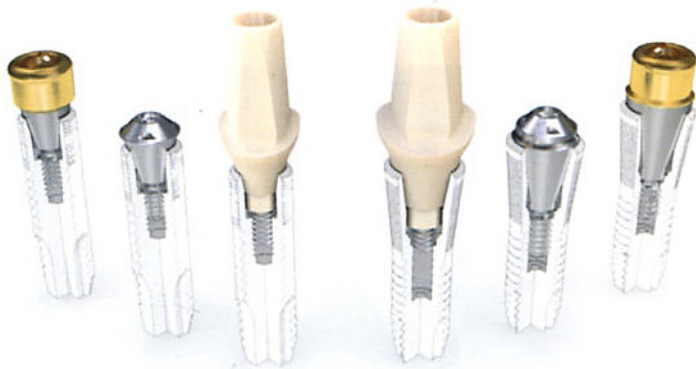
In the esthetic region, an ideal abutment option is the Ceramic Abutment made of zirconia. This is

because the shade of the abutment is closer to that of a natural tooth than its metal equivalent. There is additionally the ability to custom shape, stain and color this abutment with addition ceramics and subtraction if necessary. The crown restoration can then be fabricated from a highly esthetic ceramic material. However, due to variability in the exact surgical positioning of an implant, the ceramic abutment may not always be the best

option. The telescopic screw path of an implant should line up with the incisal edge of the adjacent anterior teeth. If the implant is angled too much in any direction, the abutment will need to be excessively reduced leaving some parts of the abutment too thin, and thus subject to fracture. Additionally, if the implant is placed too deeply, there may not be enough height in the abutment to support the crown restoration, influenced also by the length of the restoration. The depth of the abutment crown margin is also important for visualization, cement removal and proper tissue health. Generally, if the implant depth is greater than 4 mm below the tissue, the ceramic abutment may not be an ideal treatment choice. When the ceramic option is not

Summary

In this two case presentation focusing on abutment selection, Ronald Cody DMD, and Jim Lawlor CDT look at the opportunities for achieving individual esthetic results with the Astra Tech dental implant system. By offering a wide variety of abutment options, the system makes it possible to address the specific factors that influence abutment selection for each individual restoration.



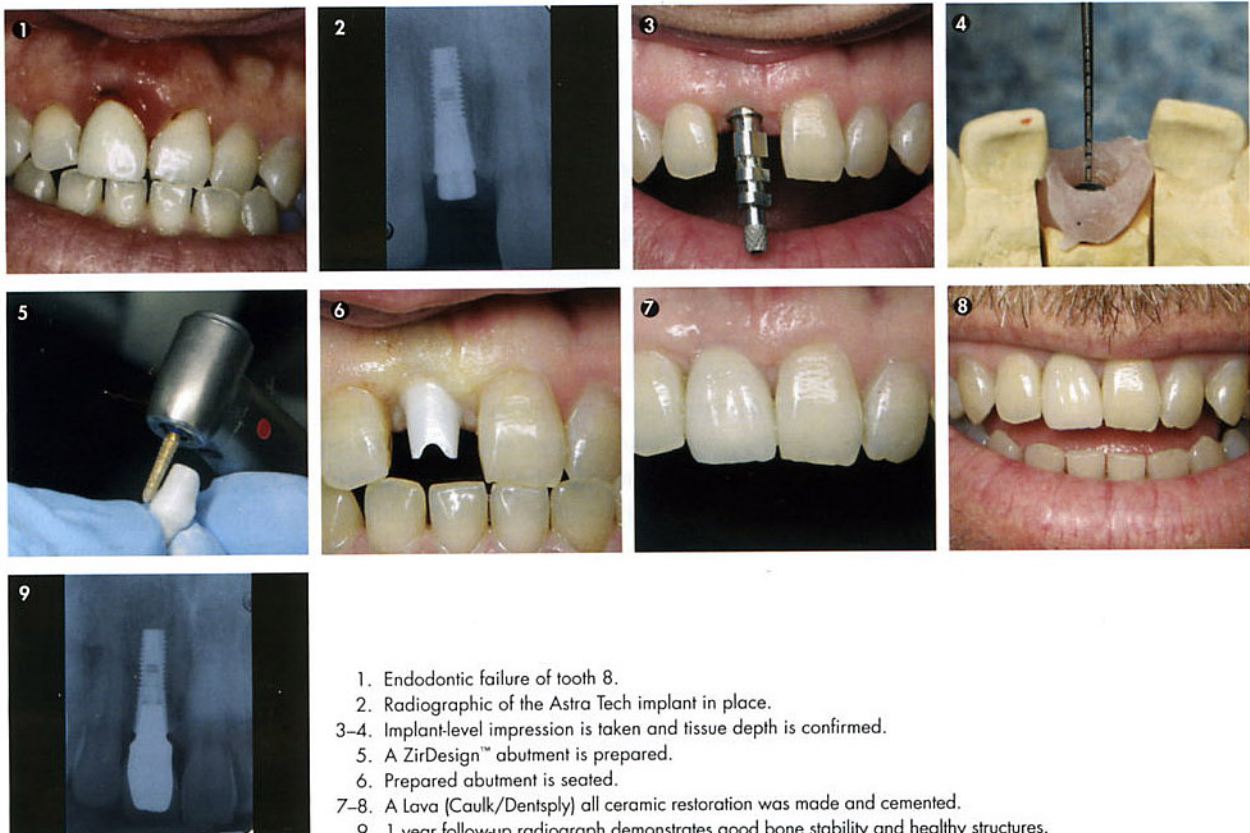
feasible, then the customizable Cast-to-Abutment is the next optimal choice. Precise placement of the margin, emergence profile, and design of the substructure to support the supra-structure restoration can be idealized in the laboratory to make the restoration biologically healthy and strong.

Case 1:

A 41-year old male patient presented with endodontic failure of tooth 8¹. Extraction and fabrication of an ovate

pontic removable temporary denture was performed. The patient was in use of a removable prosthesis during a 2 year transition period. Implant surgical placement was achieved with a precision milled template from a diagnostic matrixing of the ideal tooth position. An Astra Tech 4.5 x 13 mm implant was placed with primary stability². A healing cap was placed, and pontic was relined. Implant-level impression was made⁴. A ZirDesign™ abutment 4.5 was prepared on the stone cast to ideal dimension and polished⁵. The

abutment was seated and torqued to 25 Ncm⁶ and a temporary restoration was made. After 2 weeks, the marginal position was slightly modified and final impressions were made and sent to dental laboratory with mounted study impressions, photos, and counter impressions. A Lava (Caulk/Dentsply) all ceramic restoration was made and cemented^{7,8}. A 1 year follow-up radiograph demonstrated good bone stability and healthy structures⁹.



1. Endodontic failure of tooth 8.
2. Radiographic of the Astra Tech implant in place.
- 3-4. Implant-level impression is taken and tissue depth is confirmed.
5. A ZirDesign™ abutment is prepared.
6. Prepared abutment is seated.
- 7-8. A Lava (Caulk/Dentsply) all ceramic restoration was made and cemented.
9. 1 year follow-up radiograph demonstrates good bone stability and healthy structures.

Case 2:

A 35-year old male patient presented with endodontic failure of tooth 9^{1,2}. Extraction and immediate implant placement 4.5 x 13 mm with cover screw was performed using a precision surgical guide³. A removable partial denture with ovate pontic design was fit over the area and relined to offer tissue support during the healing process. After 4 months, the implant was surgically accessed, the healing abutment placed and the pontic relined⁴.

An implant-level impression was made and sent to the dental laboratory⁵. A gold Cast-to Abutment was fabricated and delivered to 25 Ncm⁶ and temporary crown fabricated. After 8 weeks, the margins of the Cast-to Abutment were adjusted, temporary crown relined, and final impressions were made and sent to

the dental laboratory with photos and mounted study casts. A porcelain fused to yellow gold (Brite Gold) crown was fabricated and cemented^{7,8}. A 16-month follow-up radiograph demonstrated good bone stability and healthy structures⁹.

Horizontal and vertical variability in ideal implant position can occur due to a multitude of individual surgical factors. Even with directive templates, restorative decisions such as extraction with immediate dental implant placement may compromise the accuracy of precision placement due to our desire to achieve primary stability and tissue preservation in the surgical site. Following placement, analysis of the implant position is critical. Obtaining high esthetic results involves careful coordination with the dental laboratory in the abutment selection process.

The Cast-to Abutment offers an excellent solution to placement variation issues. When conditions are ideal, the Ceramic Abutment is ideal for use in the anterior for achieving optimal esthetic results and is highly recommended.

With the Astra Tech implant system's Conical Seal Design™ abutment connection and MicroThread™, soft tissue health, fit, and bone healing remain excellent for all abutment applications.

Special thanks to:
John Corey DMD (South Portland, ME) and Robert Schaedel MD, DMD (South Portland, ME) for their surgical management, support and guidance. Restorations by Functional Esthetics Dental Laboratory, Lewisville, Texas. Ceramics by Kyle Swan, CDT.

